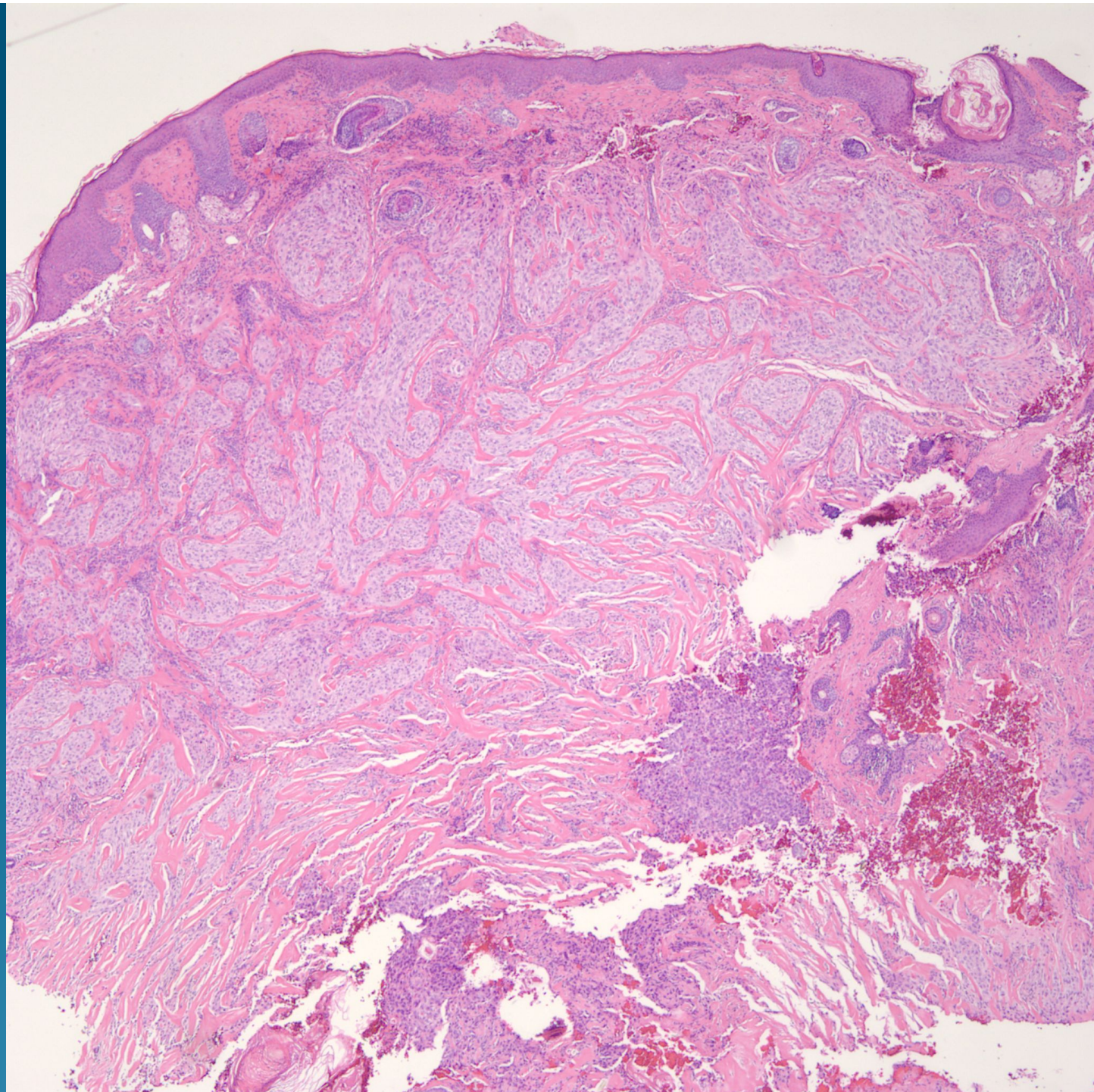
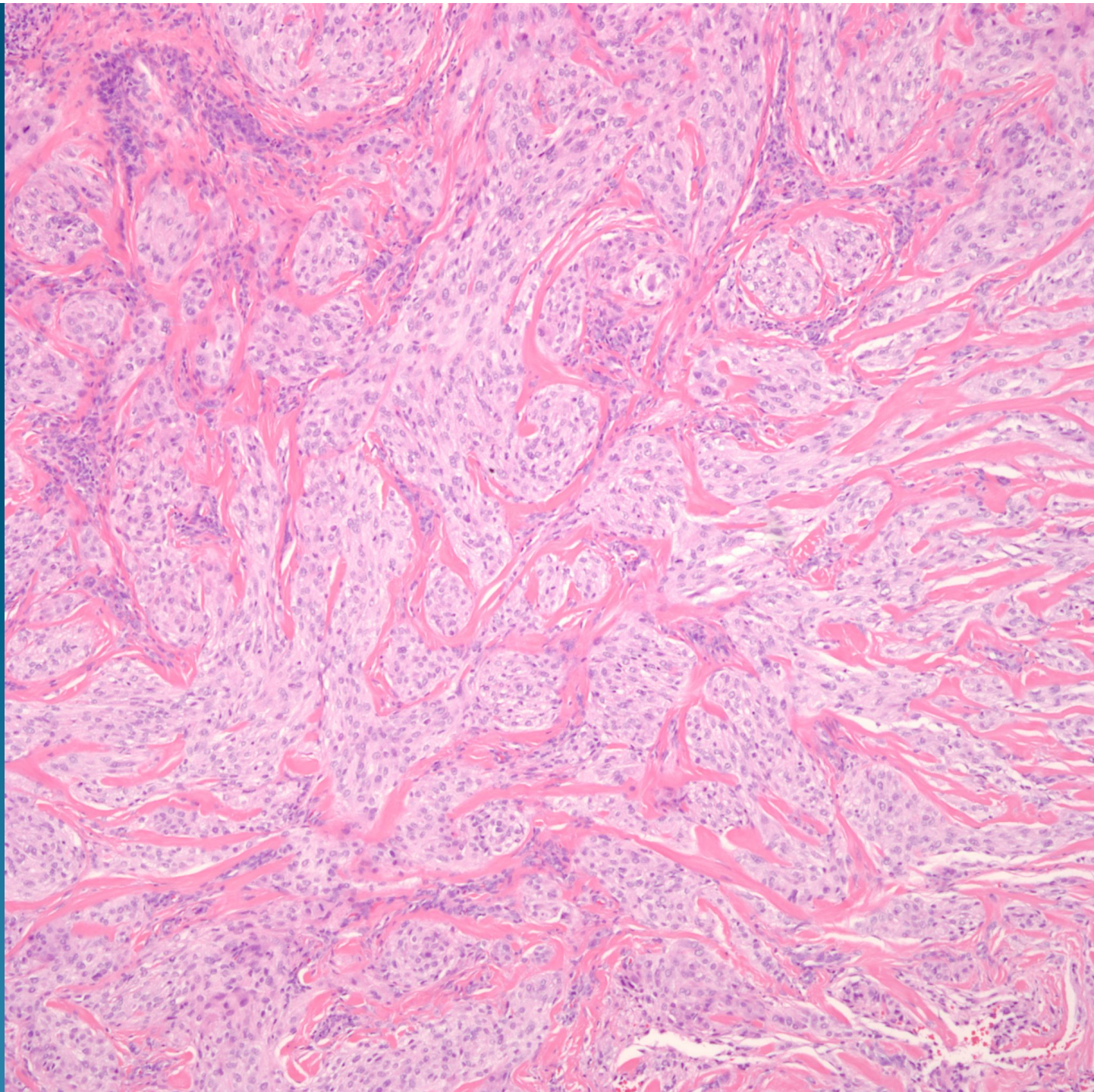
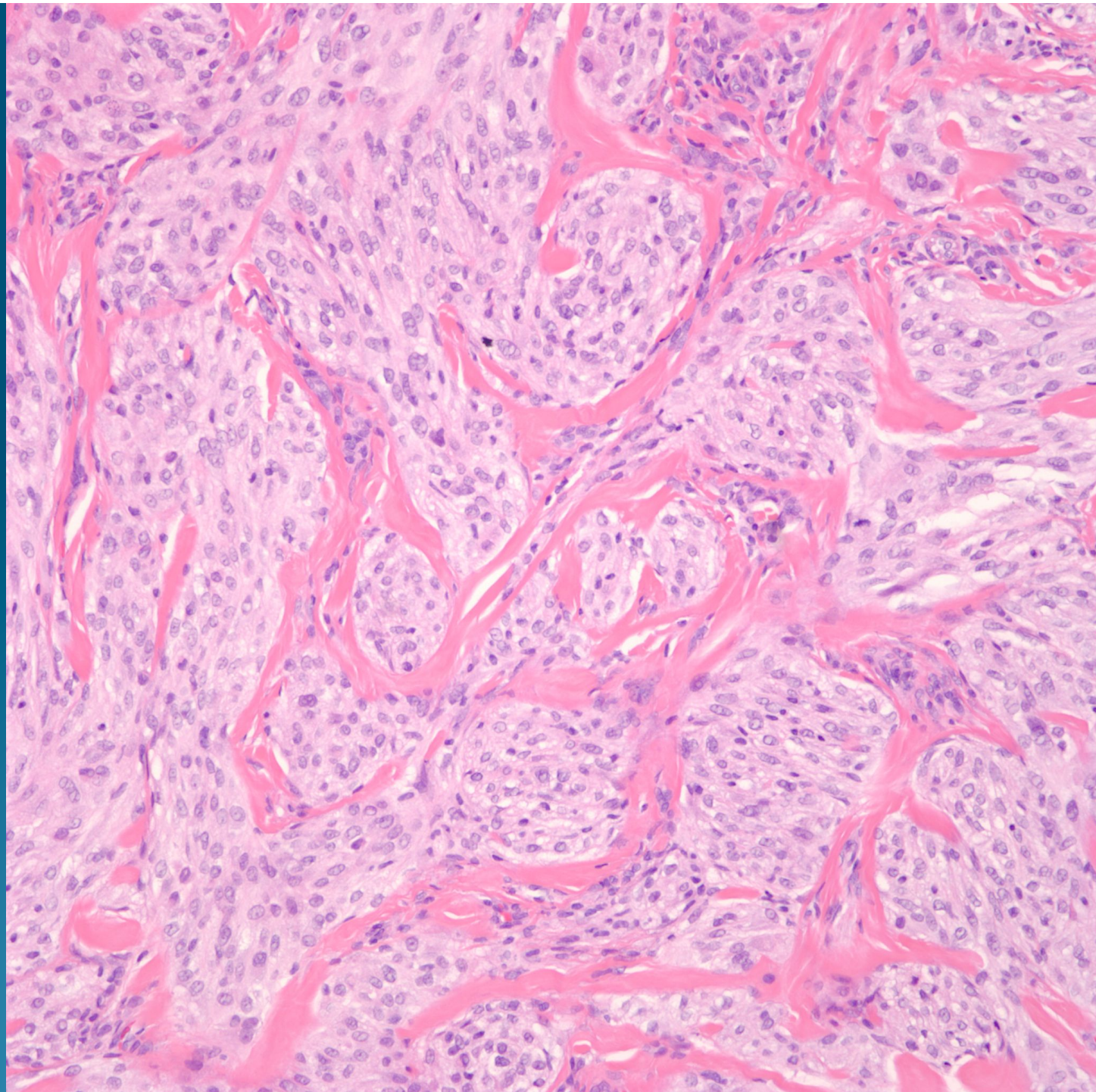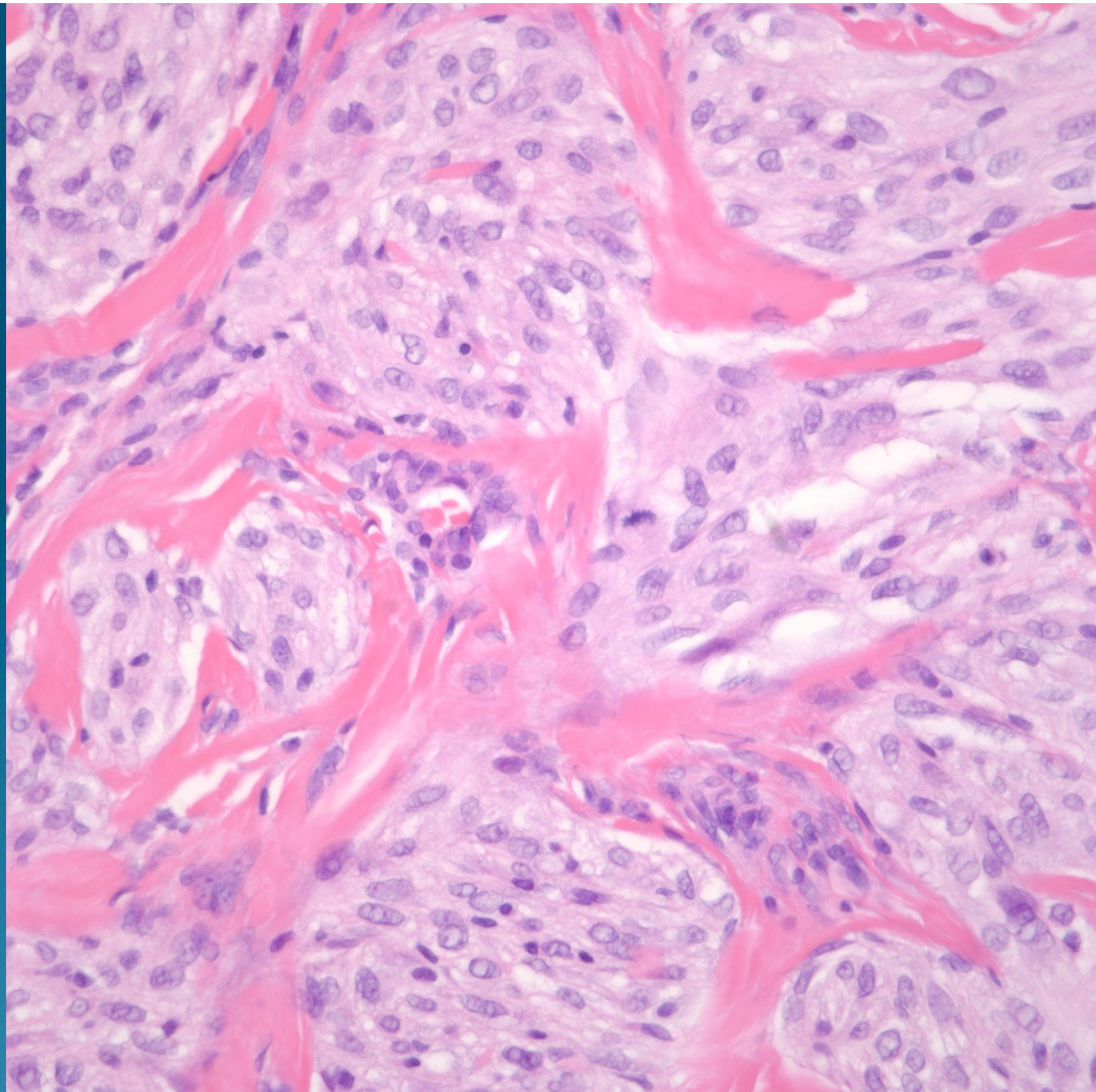# What is the best diagnosis?

- A. Dermal Spitz Nevus
- B. Palisaded and Encapsulated Neuroma
- C. Desmoplastic Melanoma
- D. Neurothekeoma
- E. Neurilemmoma

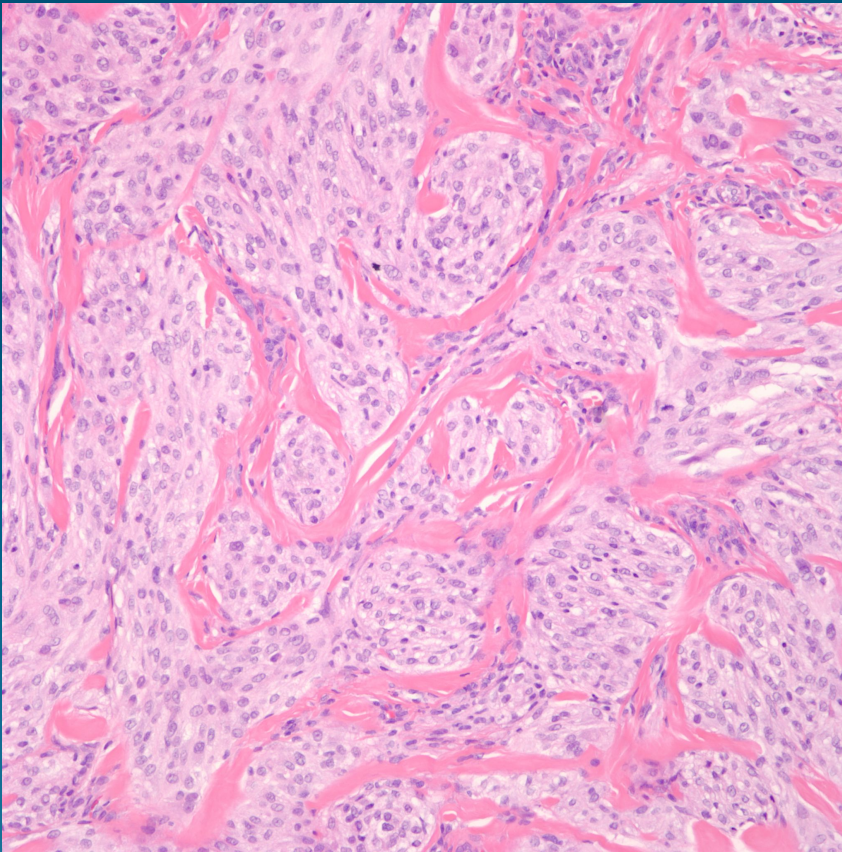
# Cellular Neurothekeoma

## Immunohistochemistry:

Negative for S100, Smooth muscle actin, HMB-45, MART-1, CD34, Factor XiiiA, Cytokeratin, EMA



# Pearls



- Dermal theques of spindled and epithelioid cells
- Dermal fibroplasia with minimal mucin
- May show focal cytologic atypia and increased mitotic figures
- Immunohistochemistry to rule out melanocytic proliferation, PEComa, and neural tumor